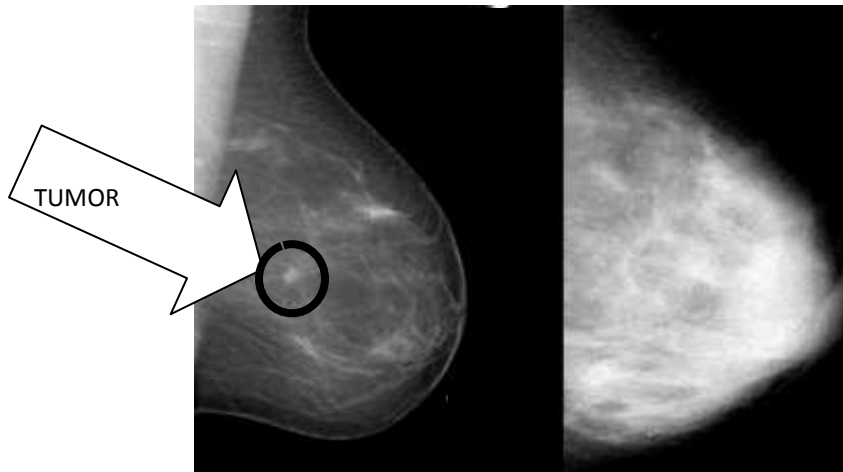


What is dense breast tissue?

Dense breast tissue is comprised of less fat and more glandular tissue. On a mammogram, dense tissue appears white and cancerous tumors appear white making it nearly impossible to "see" the tumor.



Fatty Breast

Dense Breast

On the left is a mammogram of a fatty breast. Since fat is radiolucent it produces a dark background which makes the small, white tumor in the center of the breast relatively easy to see. The mammogram on the right shows a very dense breast. It too has a cancer in roughly the same location but I challenge you to find it.

Photo from a lecture courtesy of Dr. Ellen Warner, Sunnybrook & Women's College Health Sciences, Toronto, Canada.

Are *you*
DENSE?
exposing the best-kept secret™

www.areyoudense.org